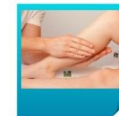

CORSO APEO:

Corso di Benessere, Make-up e Inestetismi da Terapia

Ft. Fabio Sandrin

Ft. Luiz Felipe Nevola Teixeira

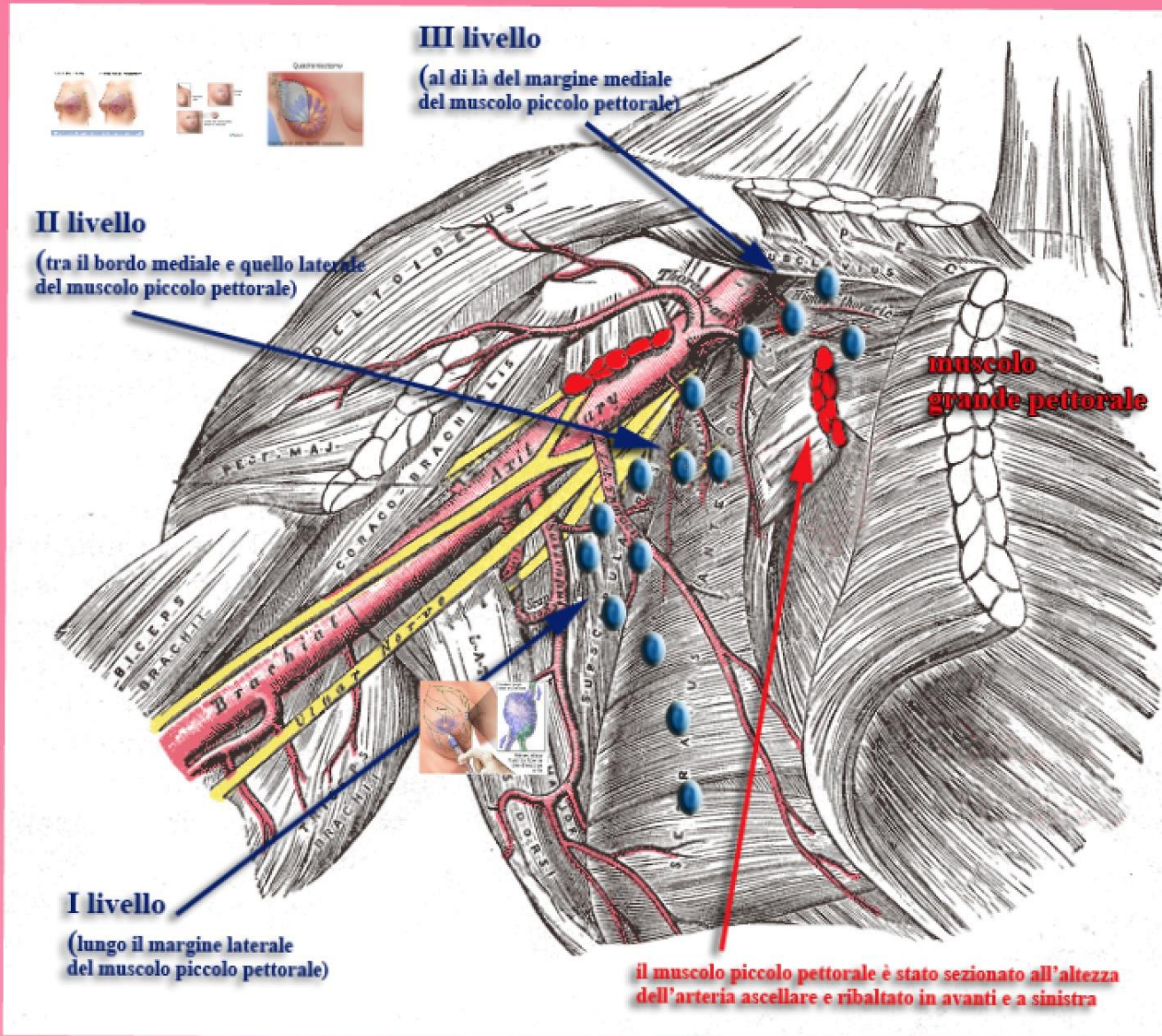


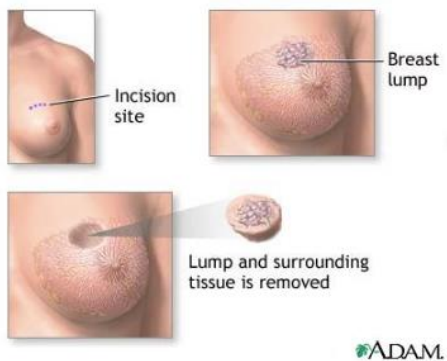Problematiche post trattamento oncologico

Definizione di sequela

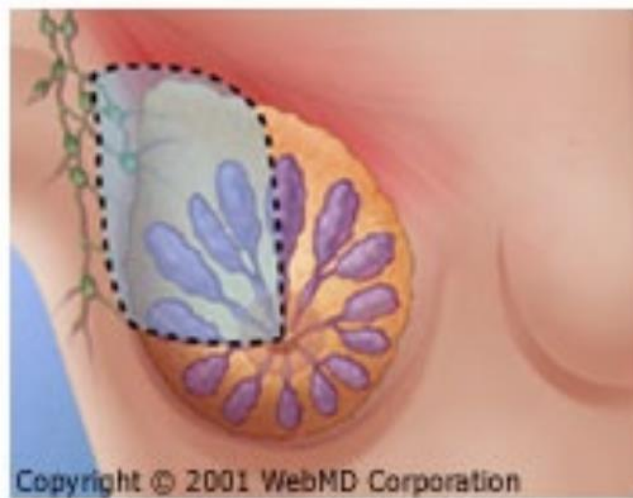
Sequela chirurgica vs sequela farmacologica

Importanza della valutazione delle sequele



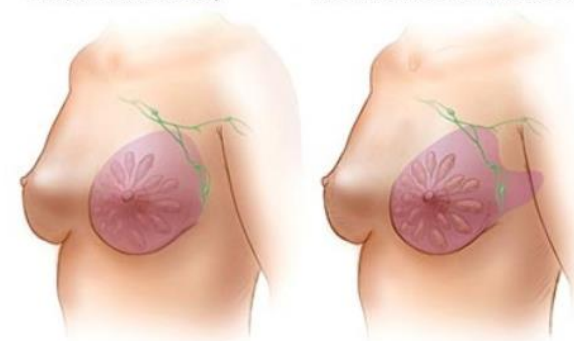


Quadrantectomy

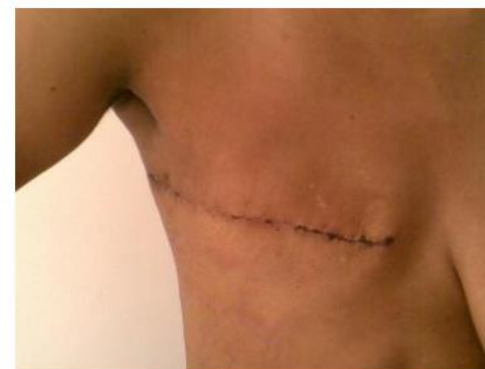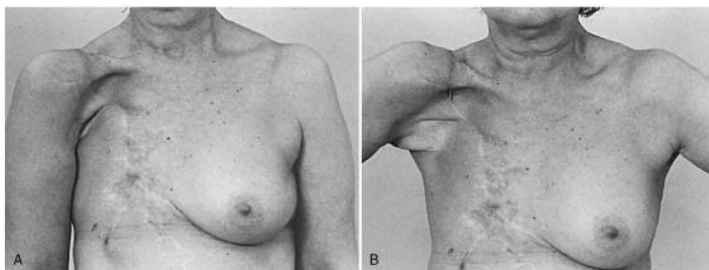


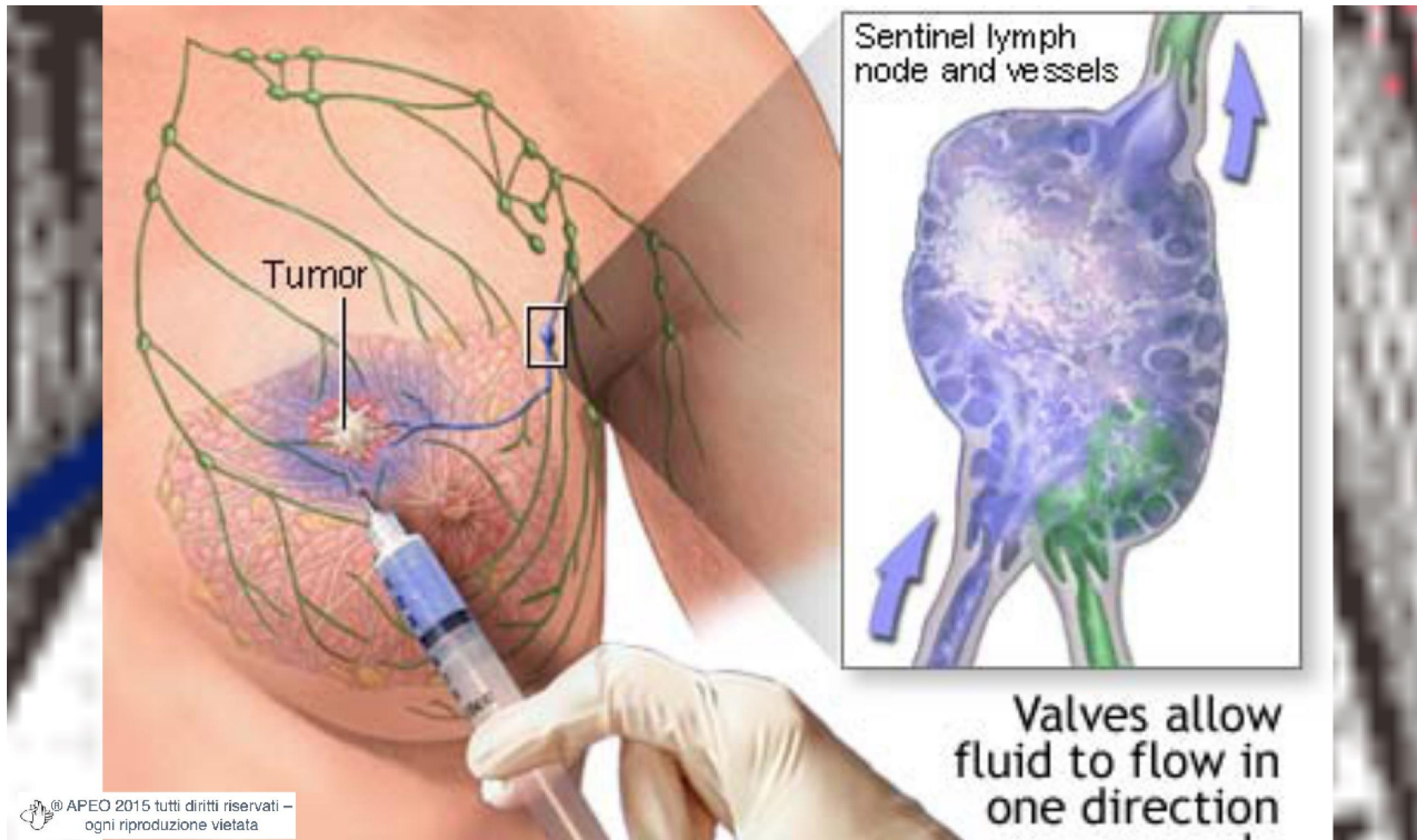
Simple mastectomy

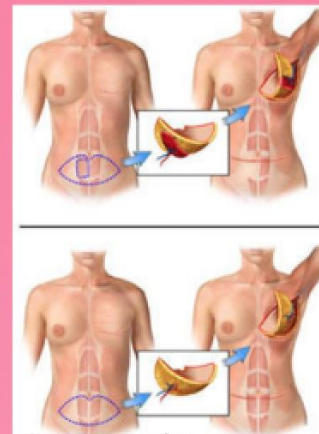
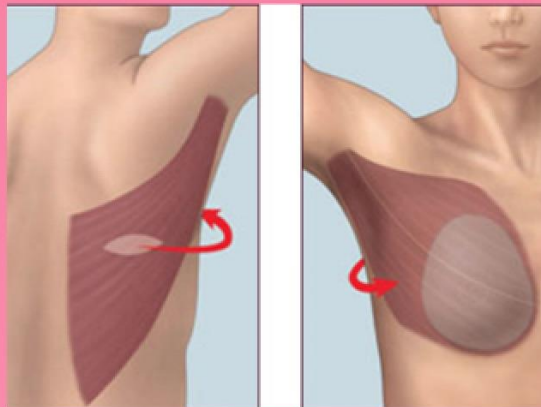
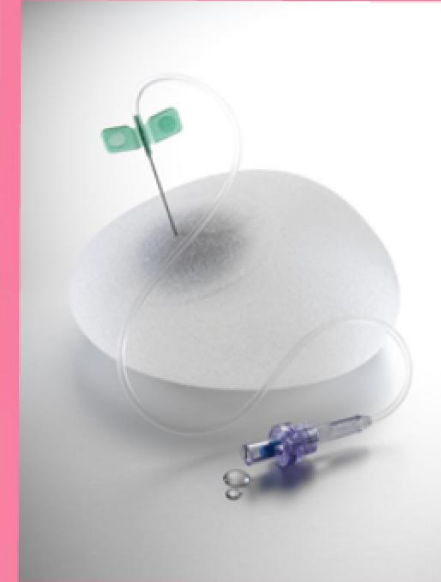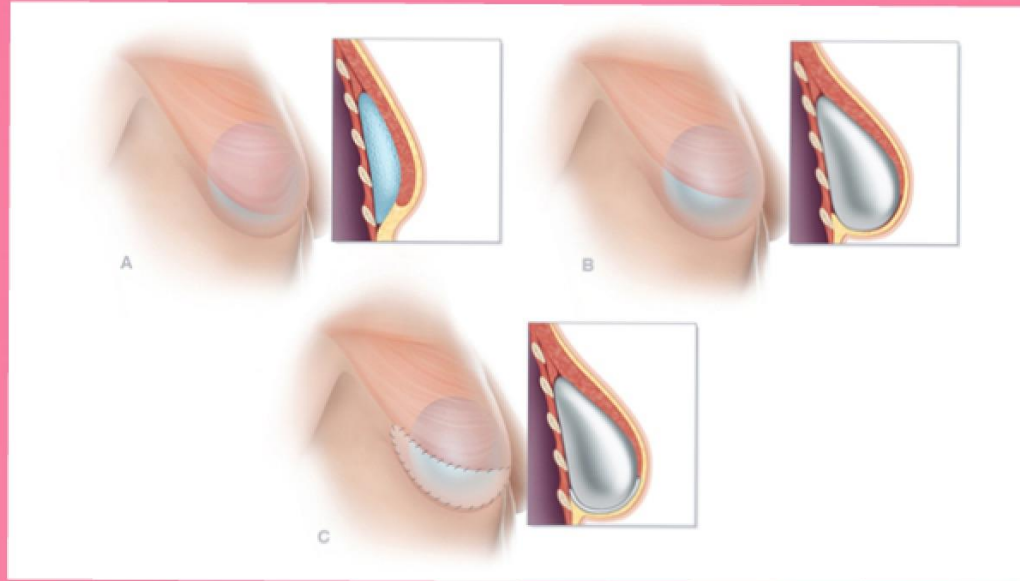
Modified radical mastectomy



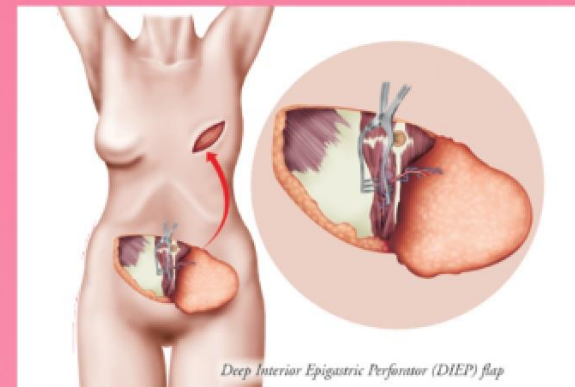
© Mayo Foundation for Medical Education and Research. All rights reserved.

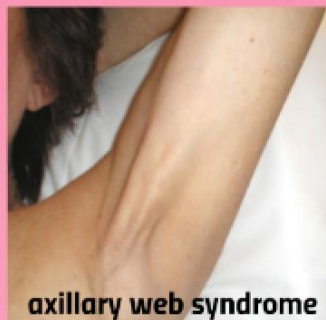




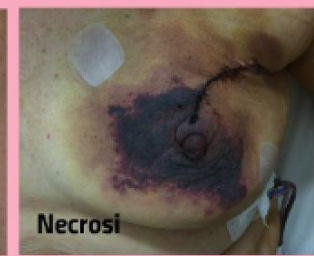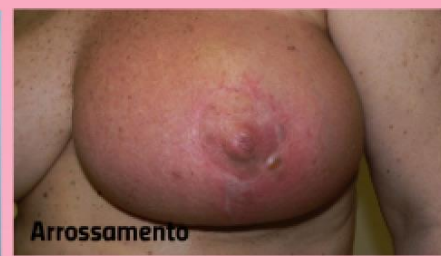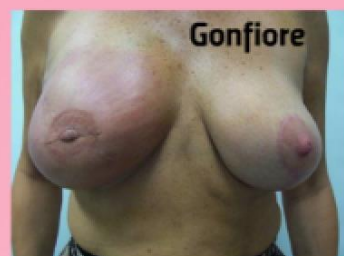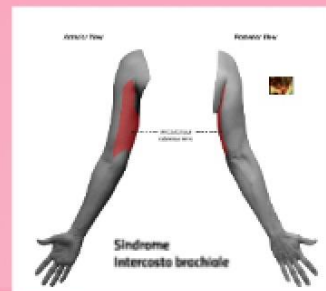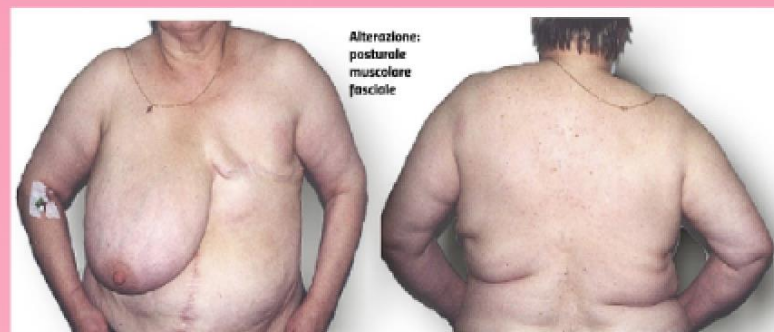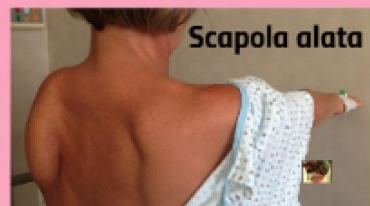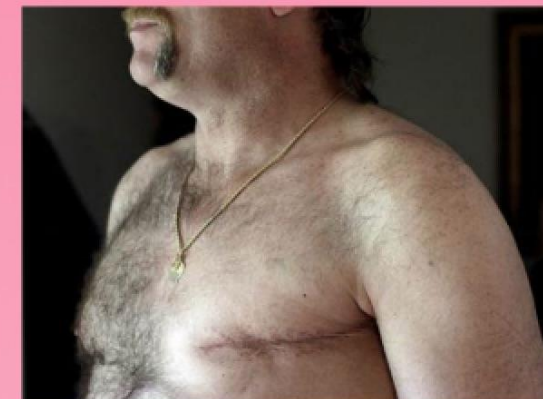


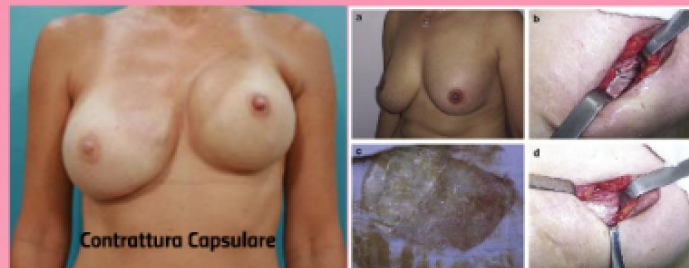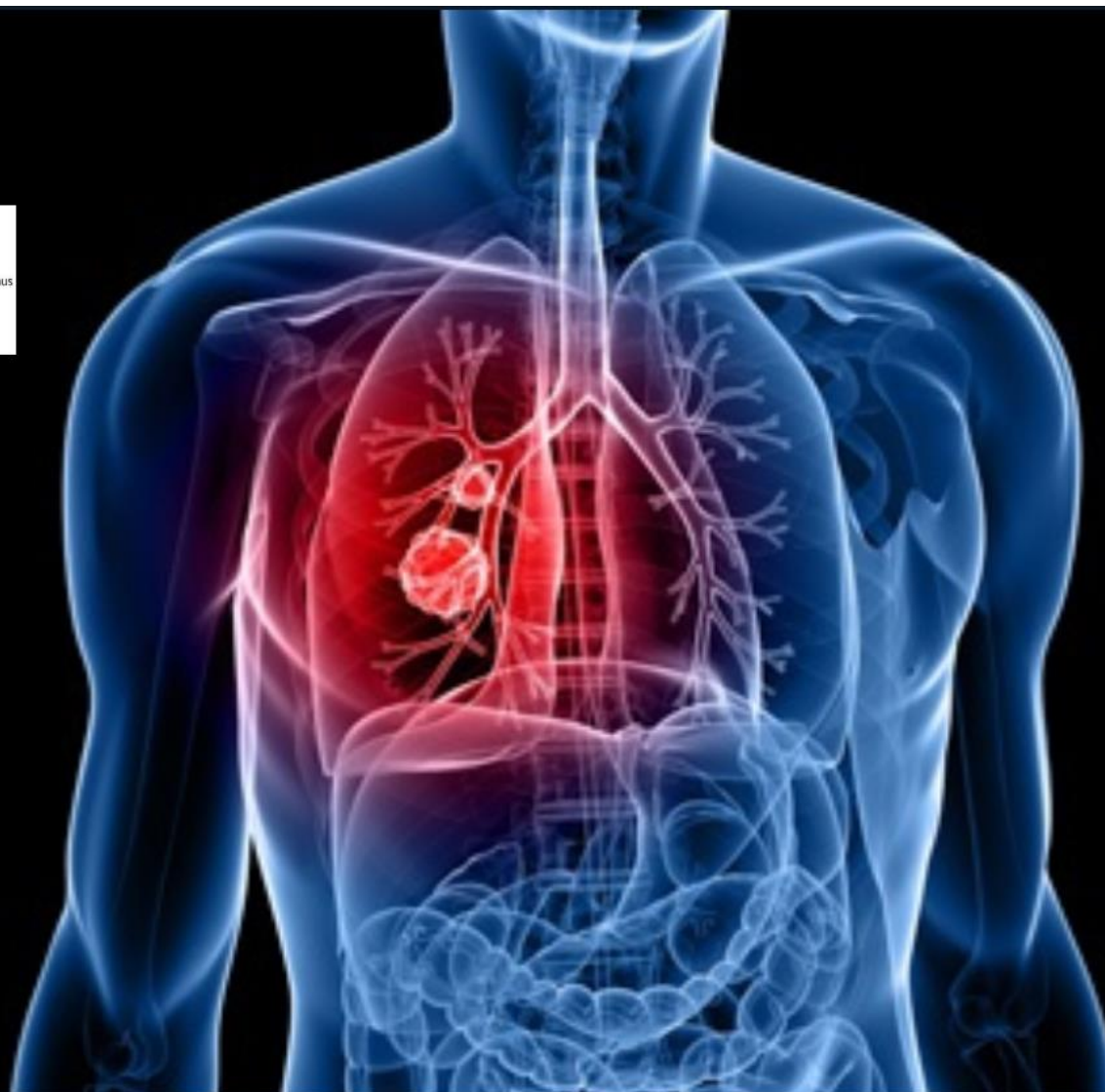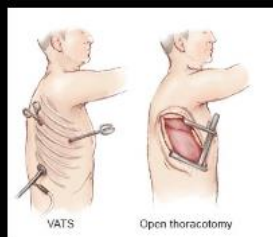
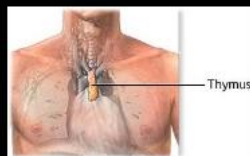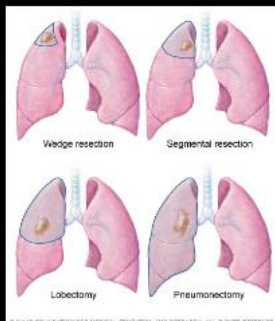
Breast Reconstruction:
Trans-Rectus Abdominus Flap Procedure
TRAM Flap





Incidenza: 36% Dissezione ascellare
 BIs: 12%
 Insorgenza: prime settimane post op
 Sintomatologia: limitazione per dolore
 Regressione: 3-6 mesi post op
 ST-AWS





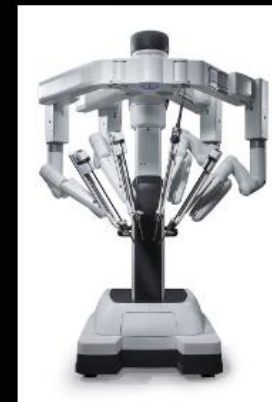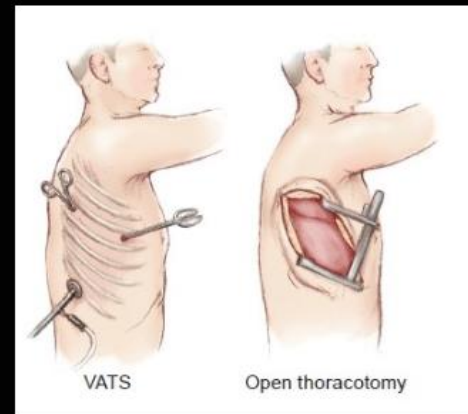
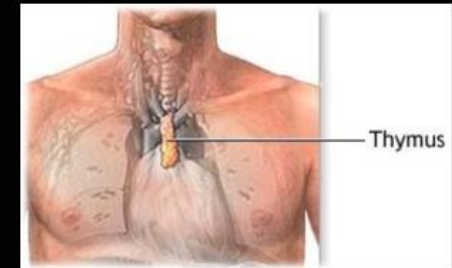
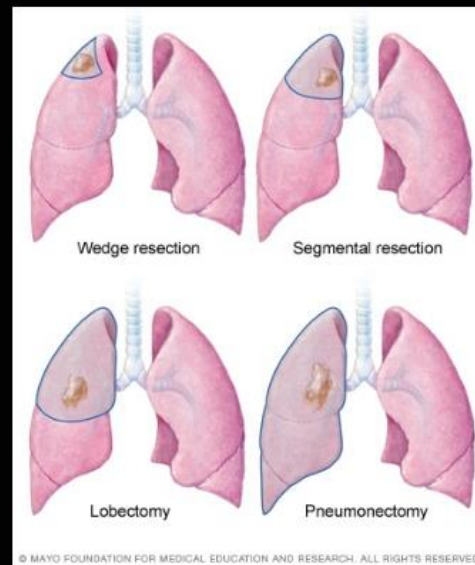
Problematiche respiratorie

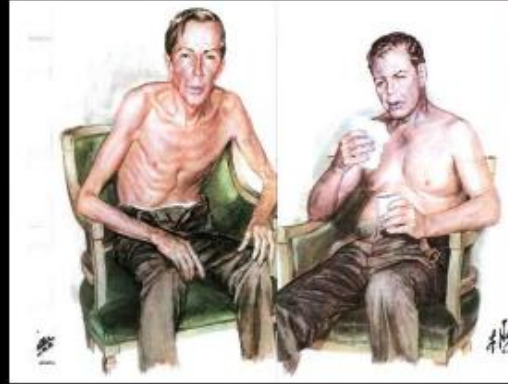Problemi articolari e muscolo fasciali

Scapola alata

Parestesie della parete toracica







Problematiche respiratorie

**Problemi articolari e
muscolo fasciali**

Scapola alata



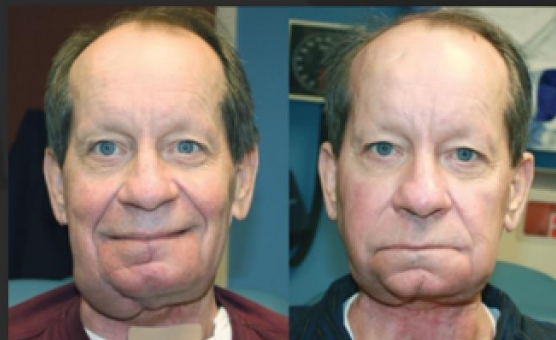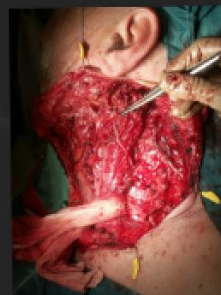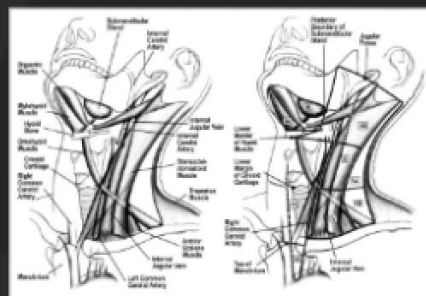
**Parestesie della parete
toracica**

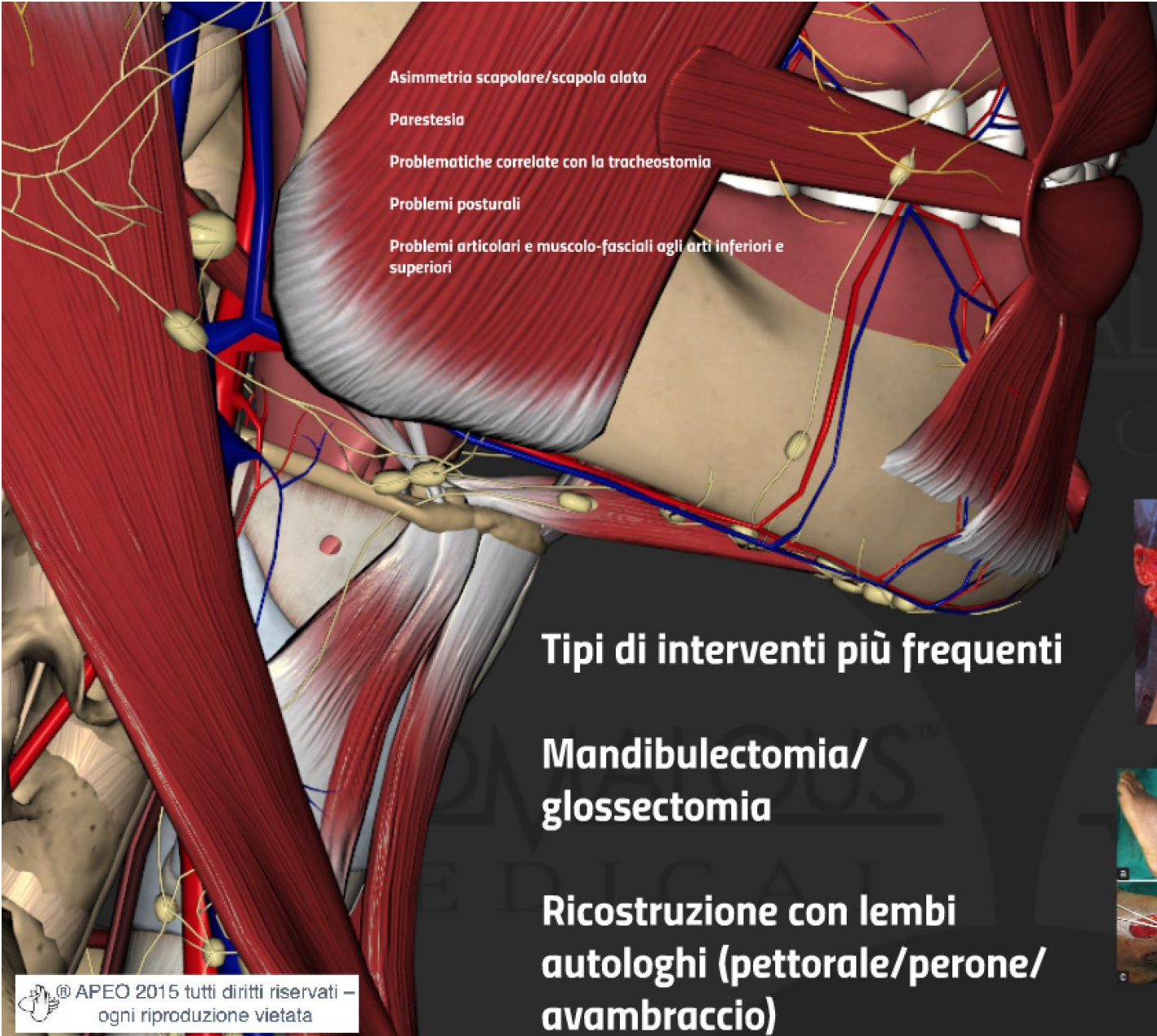


Tipi di interventi più frequenti

Laringectomia

Svuotamento latero cervicale I-V livello





Asimmetria scapolare/scapola alata

Parestesia

Problematiche correlate con la tracheostomia

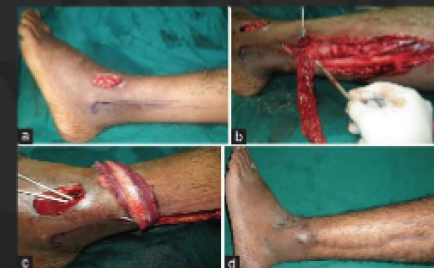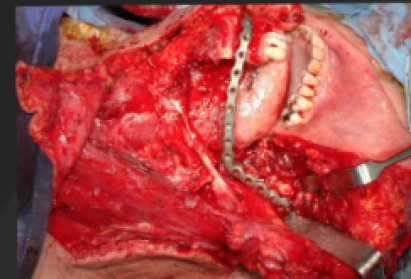Problemi posturali

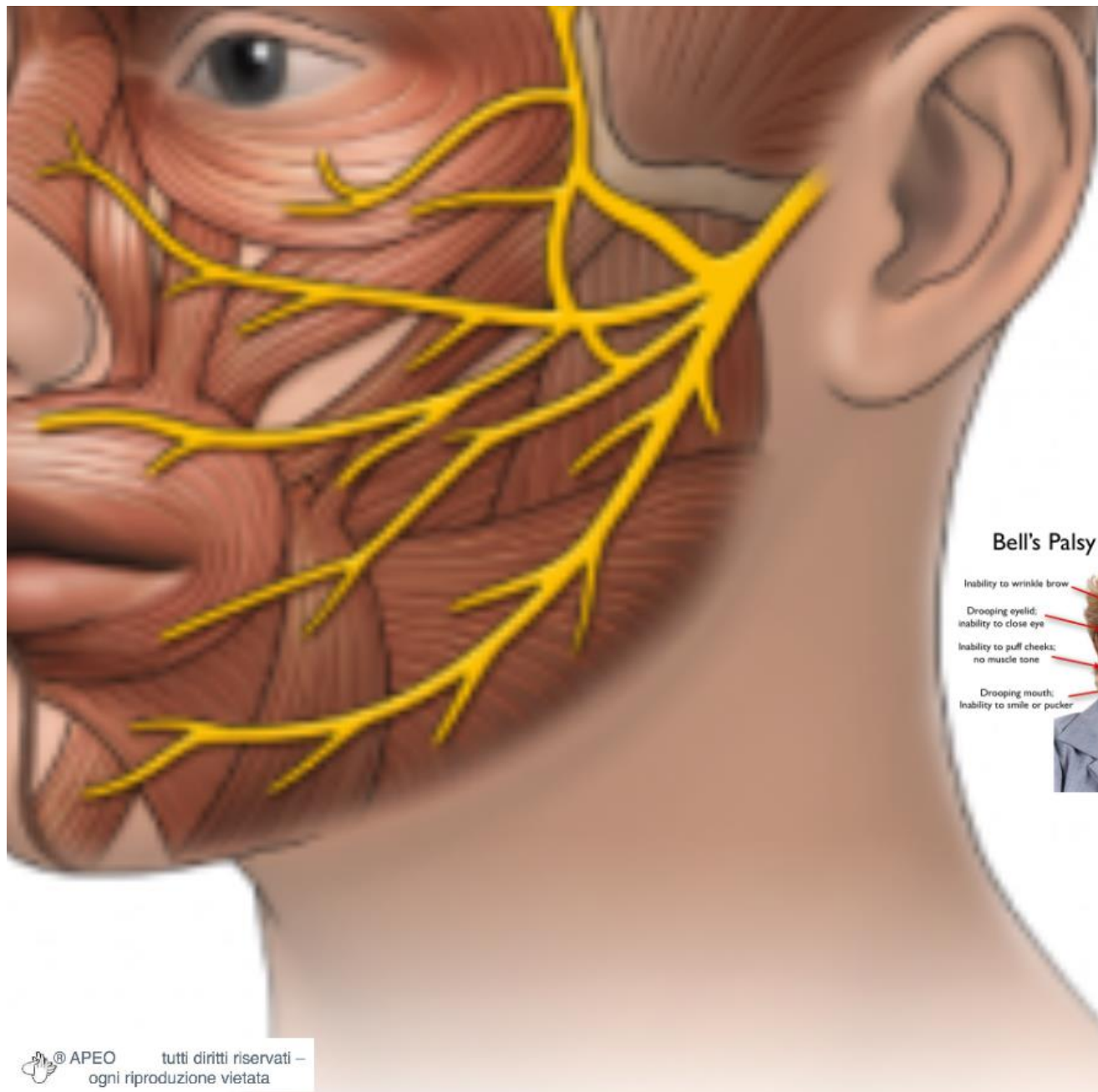
Problemi articolari e muscolo-fasciali agli arti inferiori e superiori

Tipi di interventi più frequenti

**Mandibulectomia/
glossectomia**

**Ricostruzione con lembi
autologhi (pettorale/perone/
avambraccio)**





Bell's Palsy

Inability to wrinkle brow

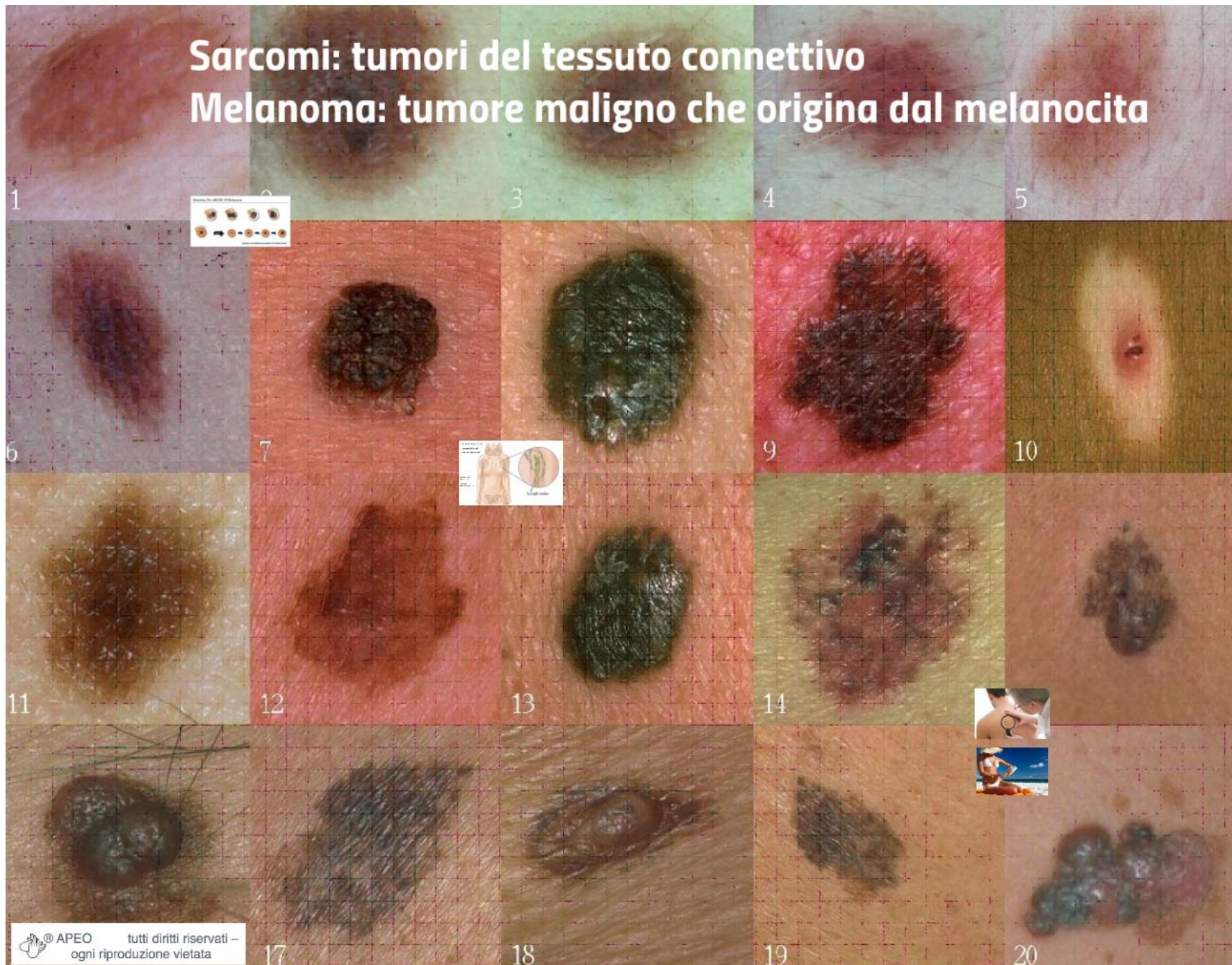Drooping eyelid;
inability to close eye

Inability to puff cheeks;
no muscle tone

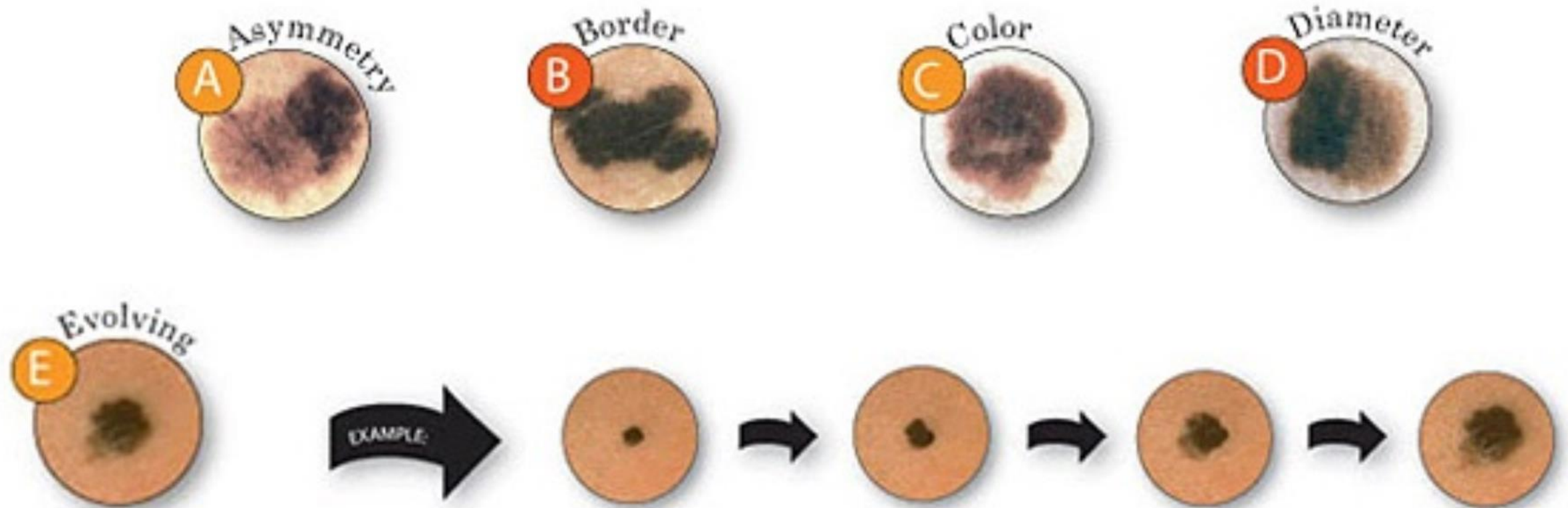
Drooping mouth;
inability to smile or pucker



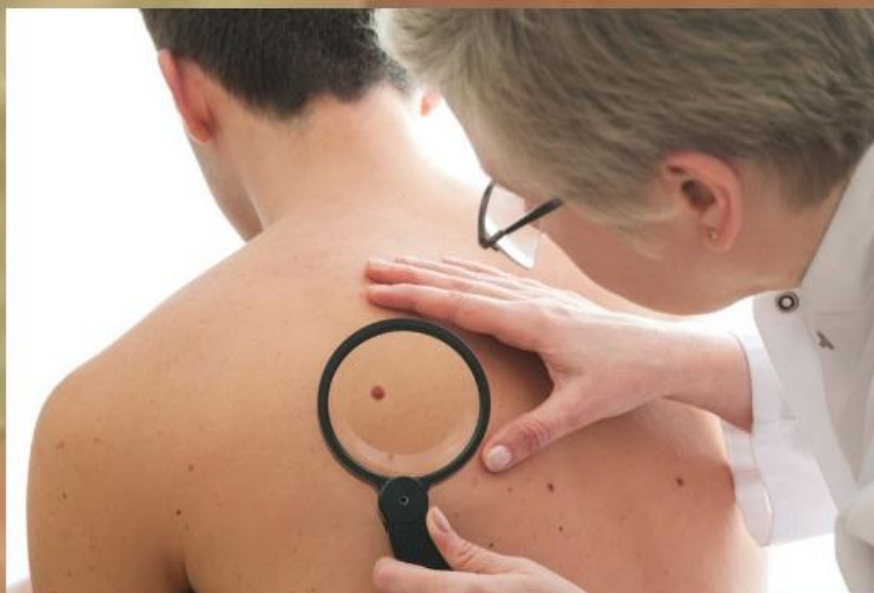Melanoma: tumore maligno che origina dal melanocita



Detecting The ABCDEs Of Melanoma



SOURCE: THE AMERICAN ACADEMY OF DERMATOLOGY



Tipi di interventi più frequenti:

Svuotamenti linfonodali

Rimozione dei tessuti molli

Deficit del nervo otturatorio

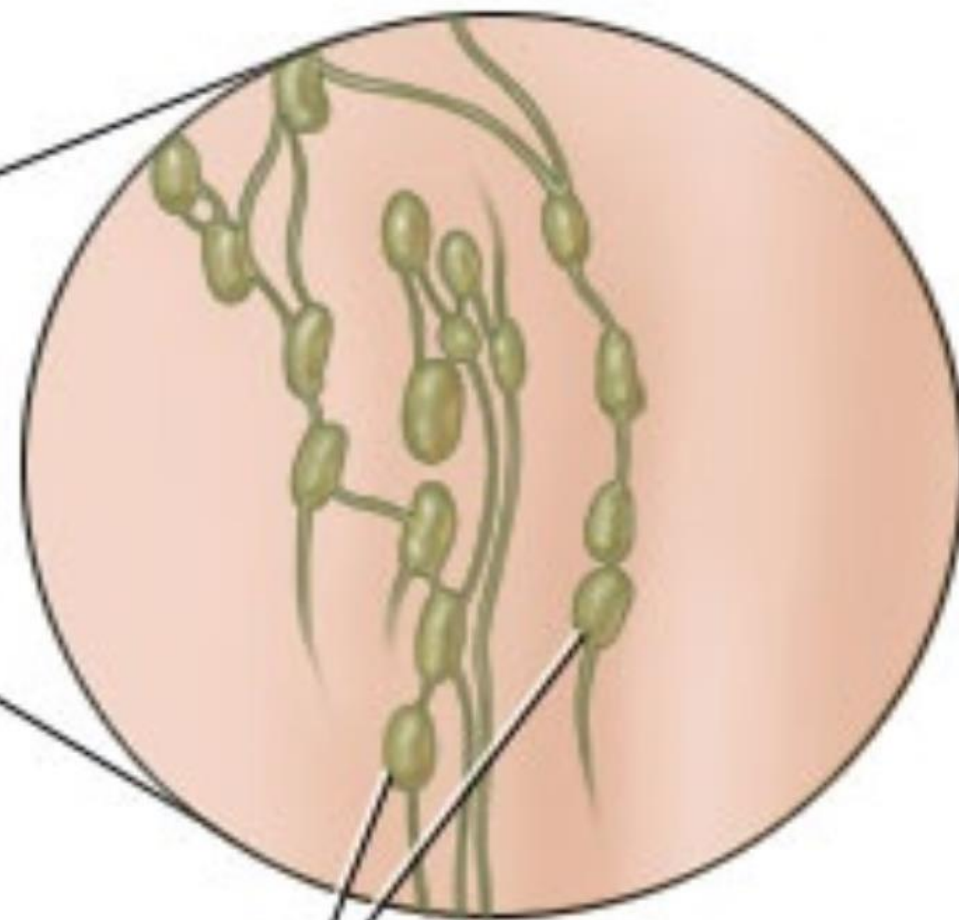
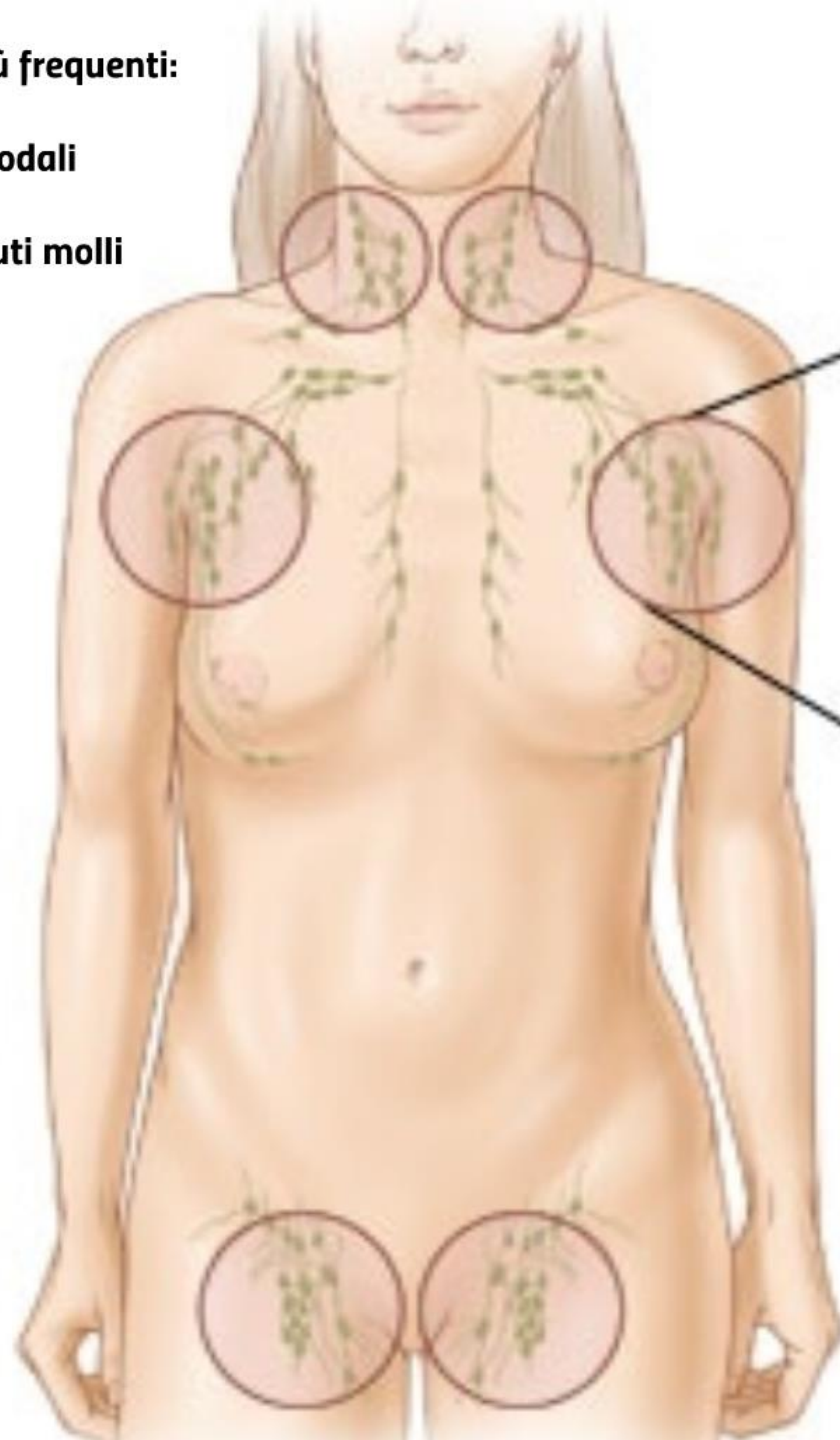
Deficit del nervo femorale

Deficit del nervo fibulare

Parestesie

Problemi posturali

Problemi articolari e muscolo-fasciali

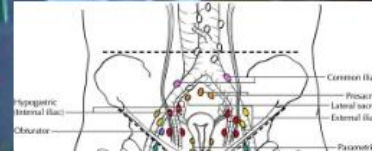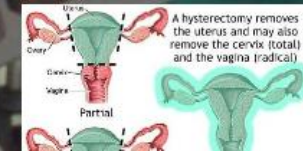

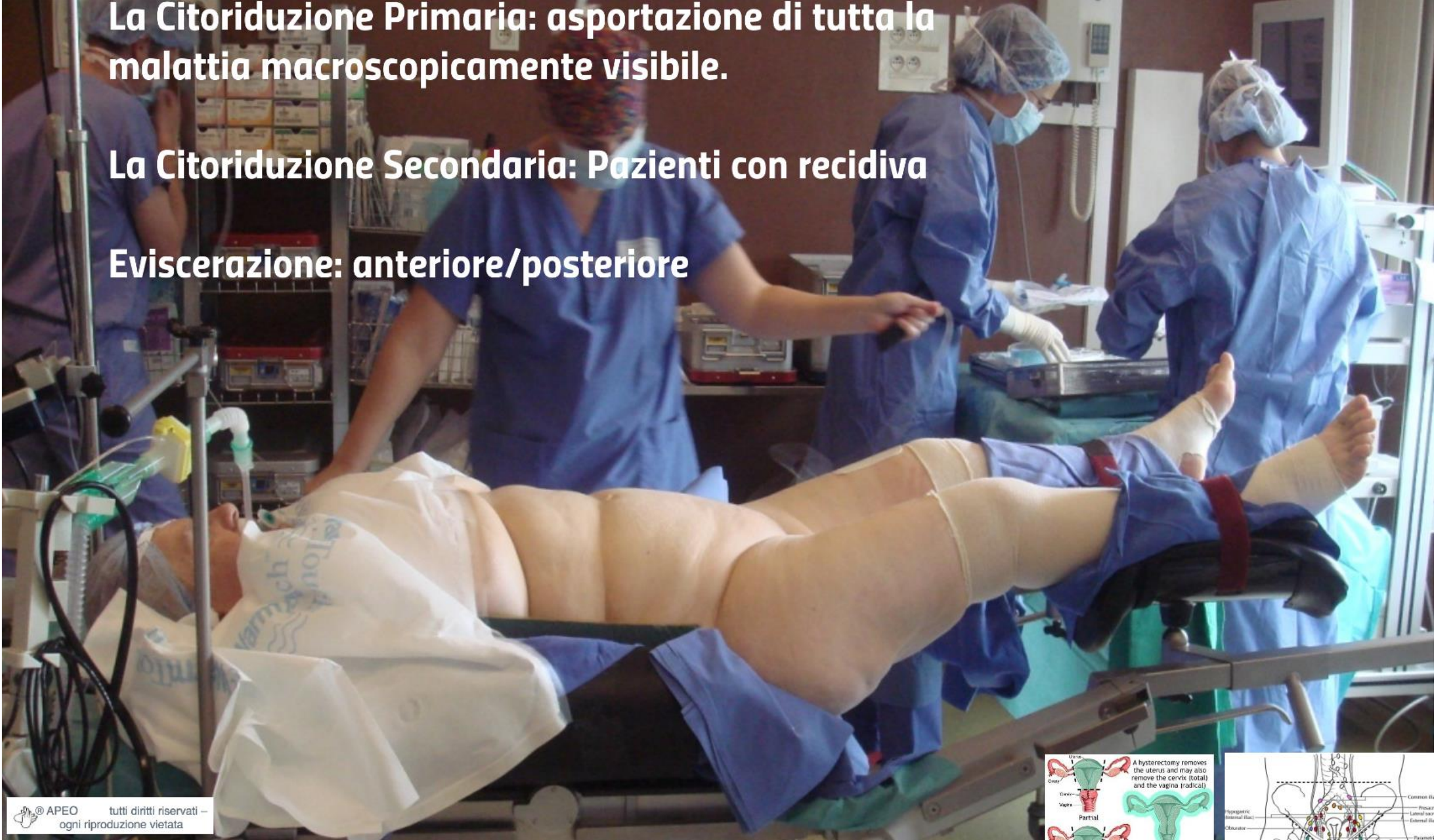
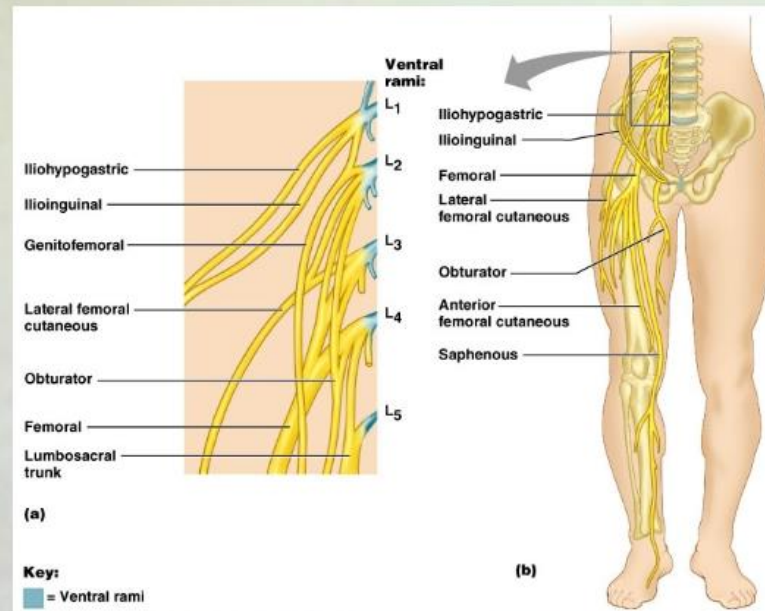
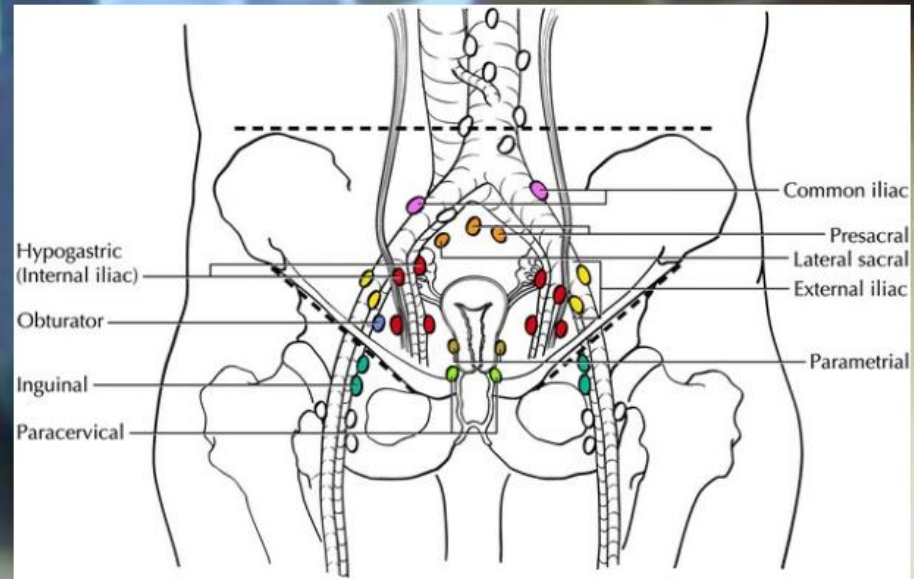
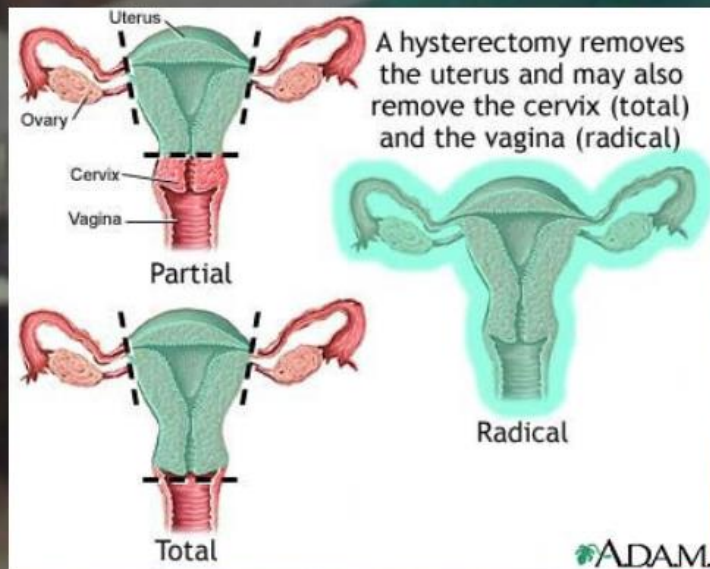
Lymph nodes

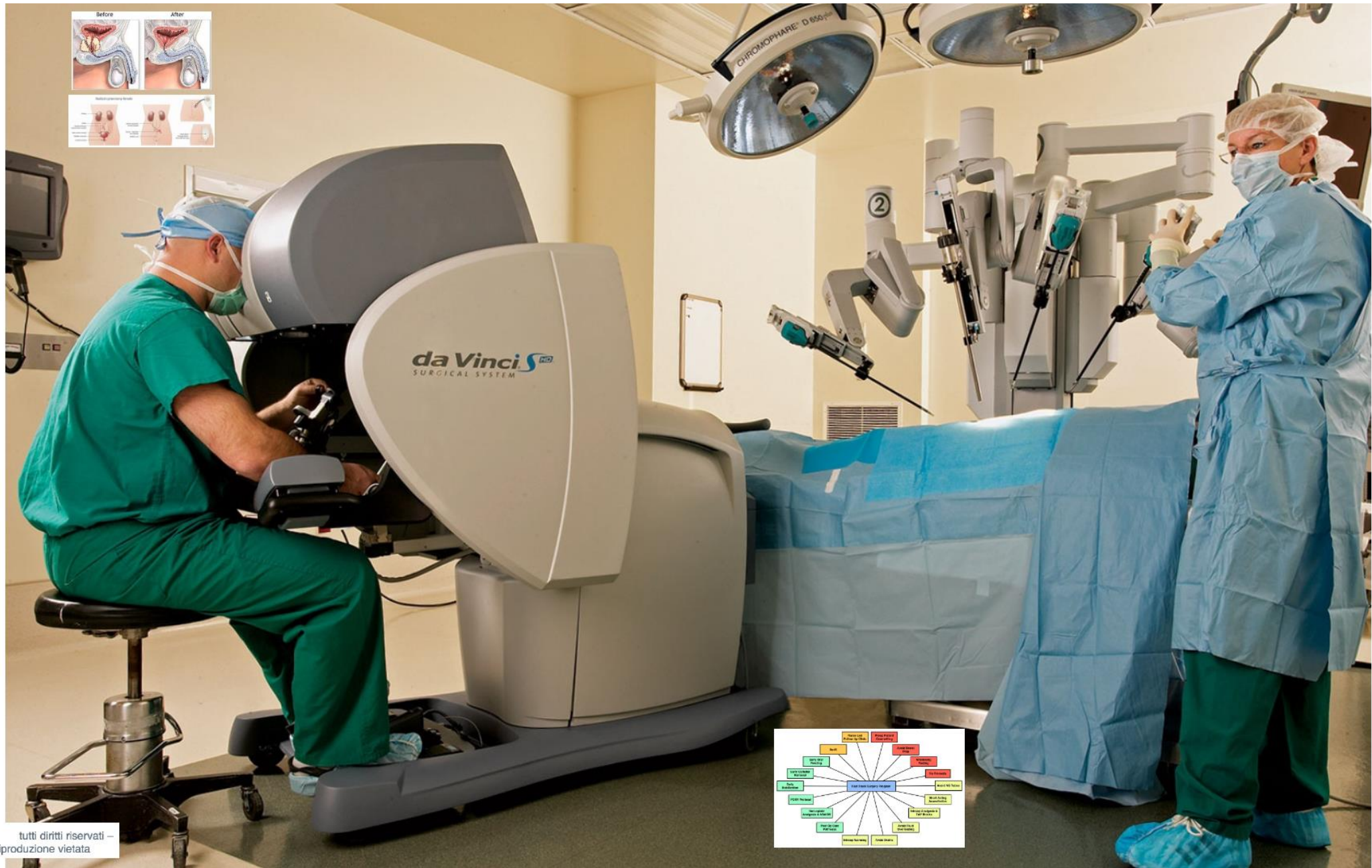**La Citoriduzione Primaria: asportazione di tutta la
malattia macroscopicamente visibile.**

La Citoriduzione Secondaria: Pazienti con recidiva

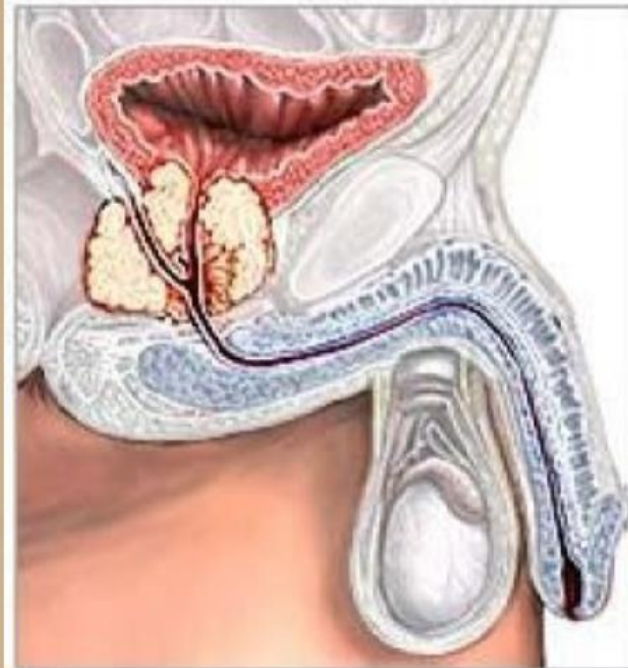
Eviscerazione: anteriore/posteriore



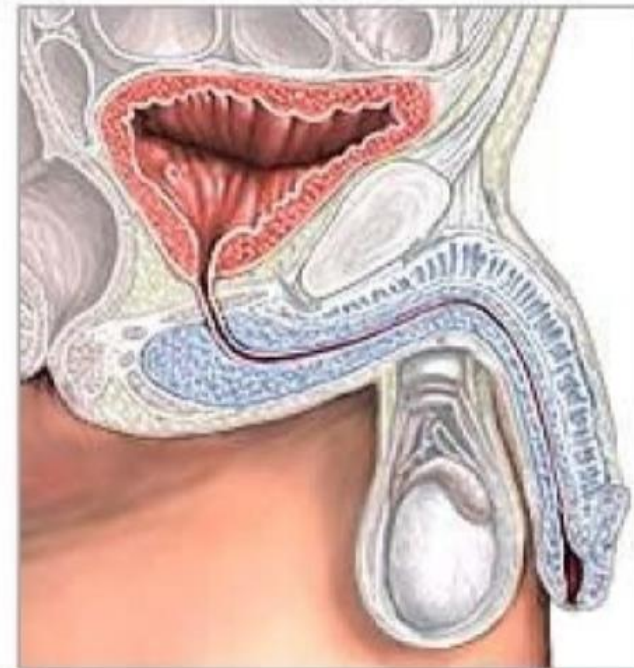




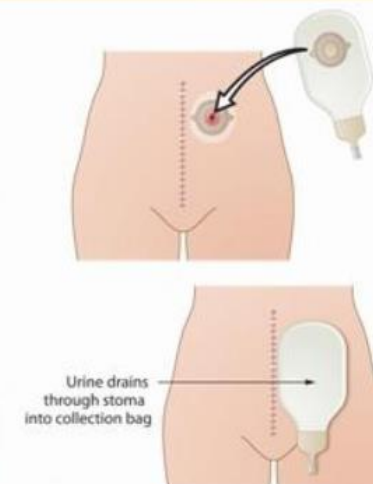
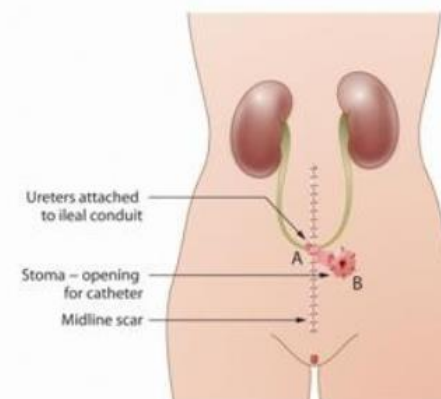
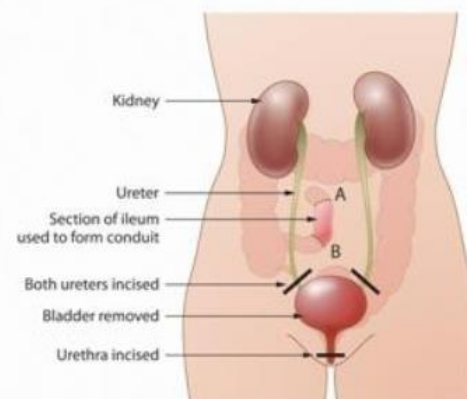
Before

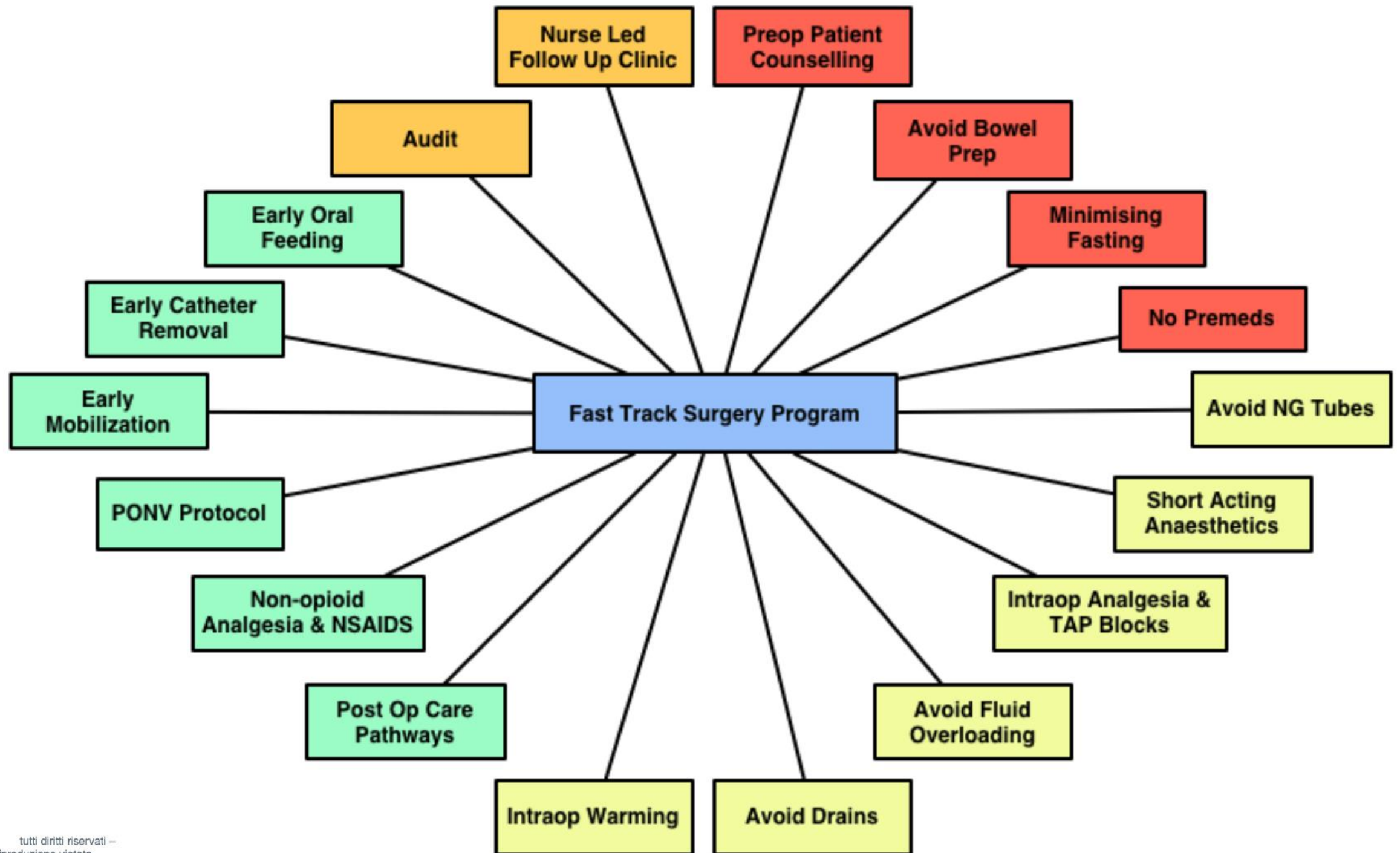


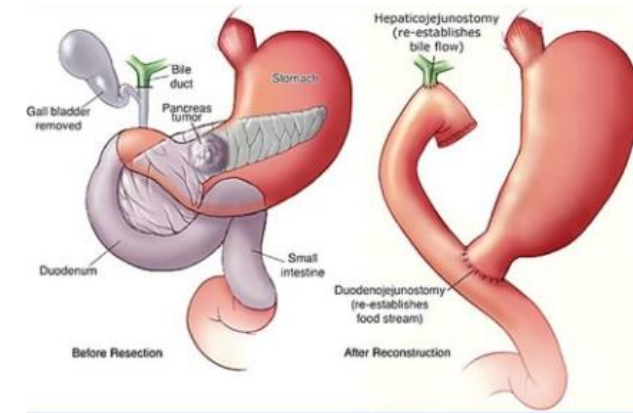
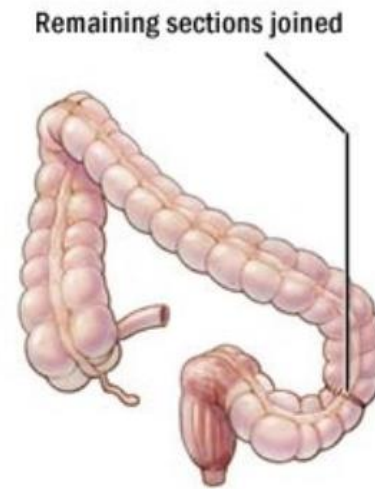
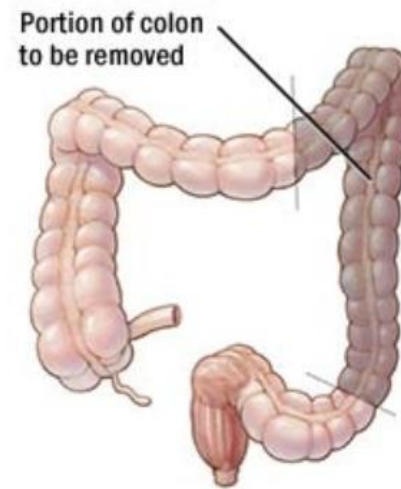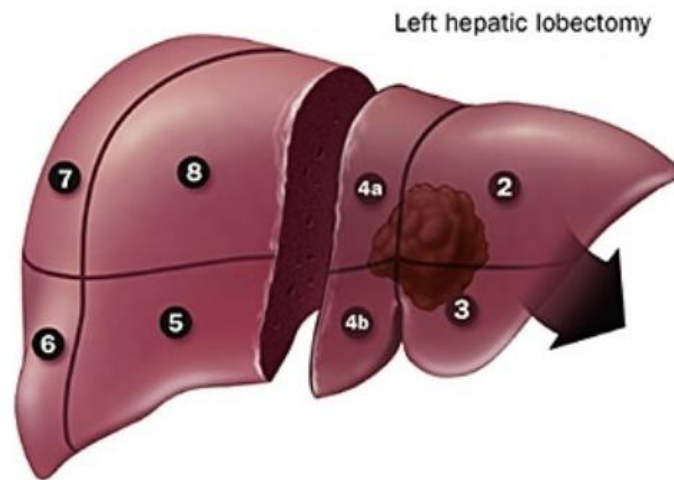
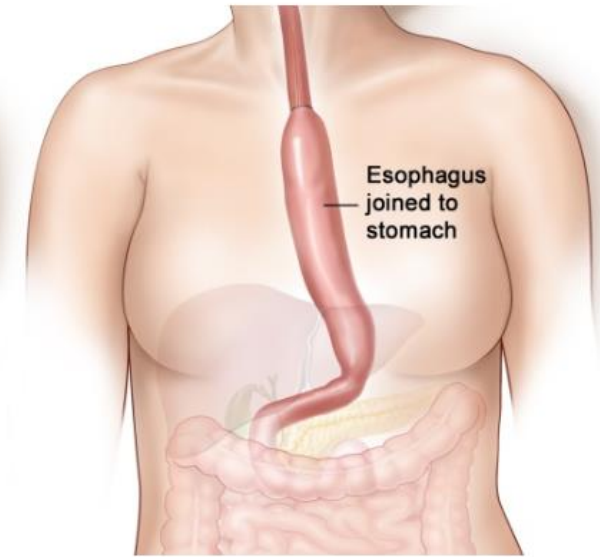
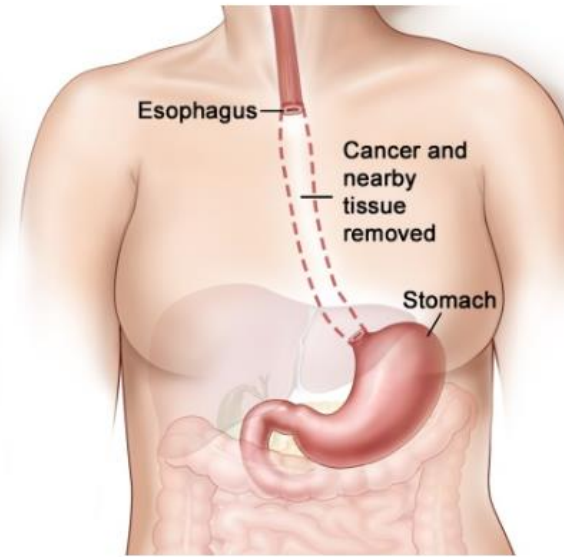
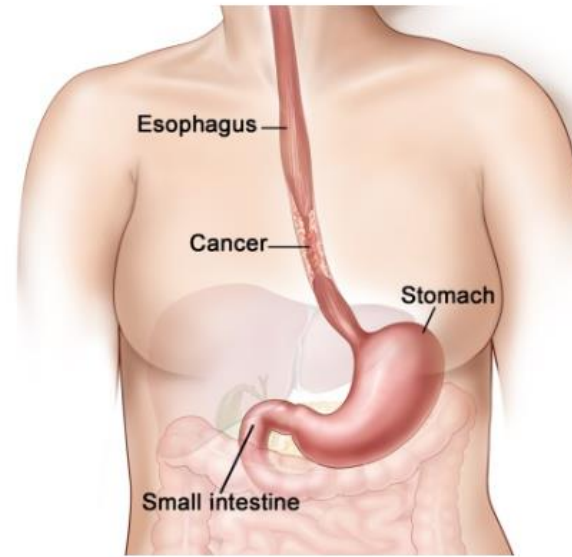
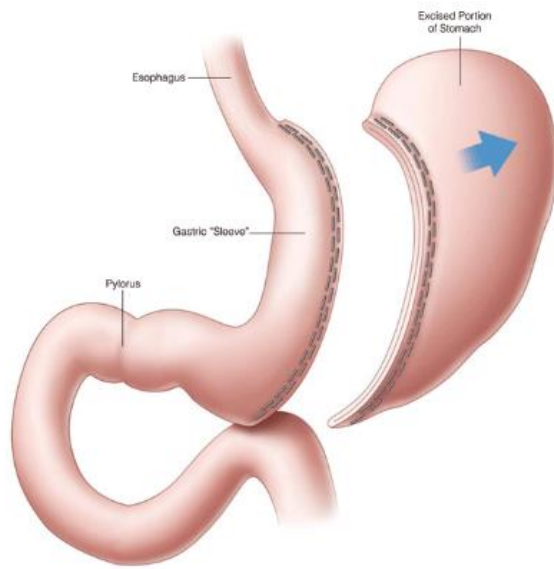
After



Radical cystectomy female







Sequela:

Deficit agli arti inferiori

Deficit della parete addominale

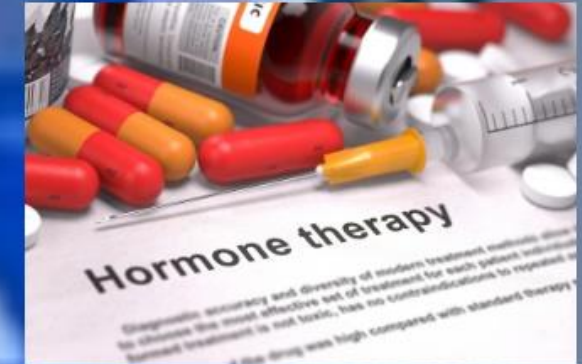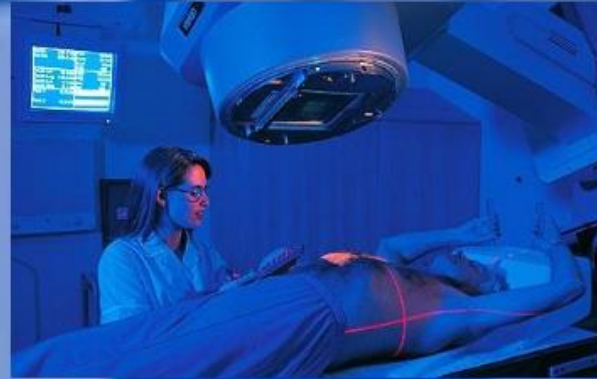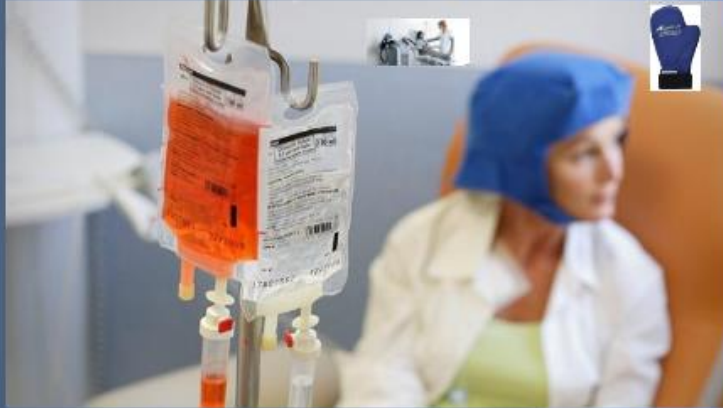Parestesia

Problemi posturali

Problemi articolari e muscolo-fasciali

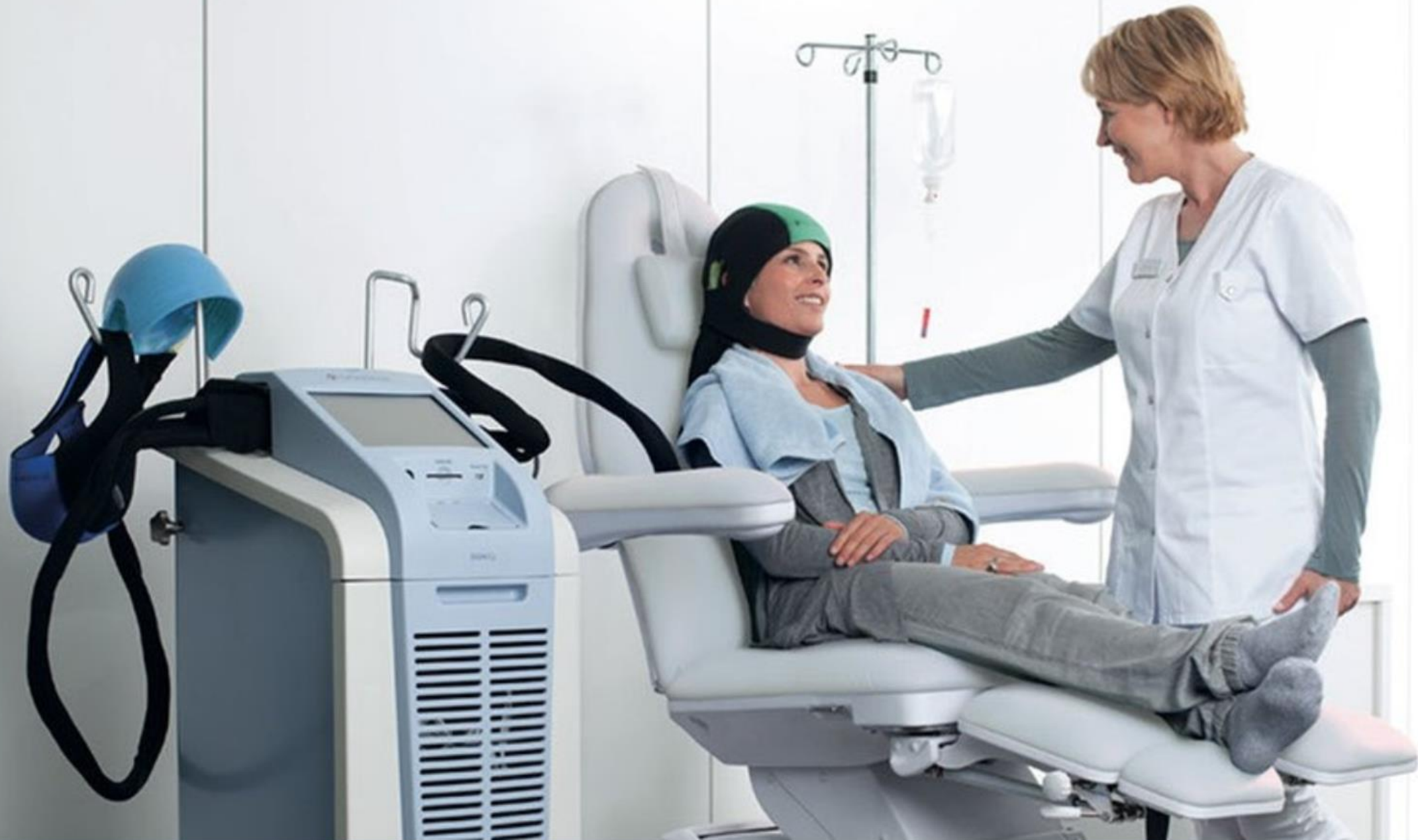Incontinenza urinaria/fecale (stomia)

Oncologia medica



Parestesia neurotossica
Artralgia e mialgia
Vampate di calore
Alterazioni cutanee
Problemi associati

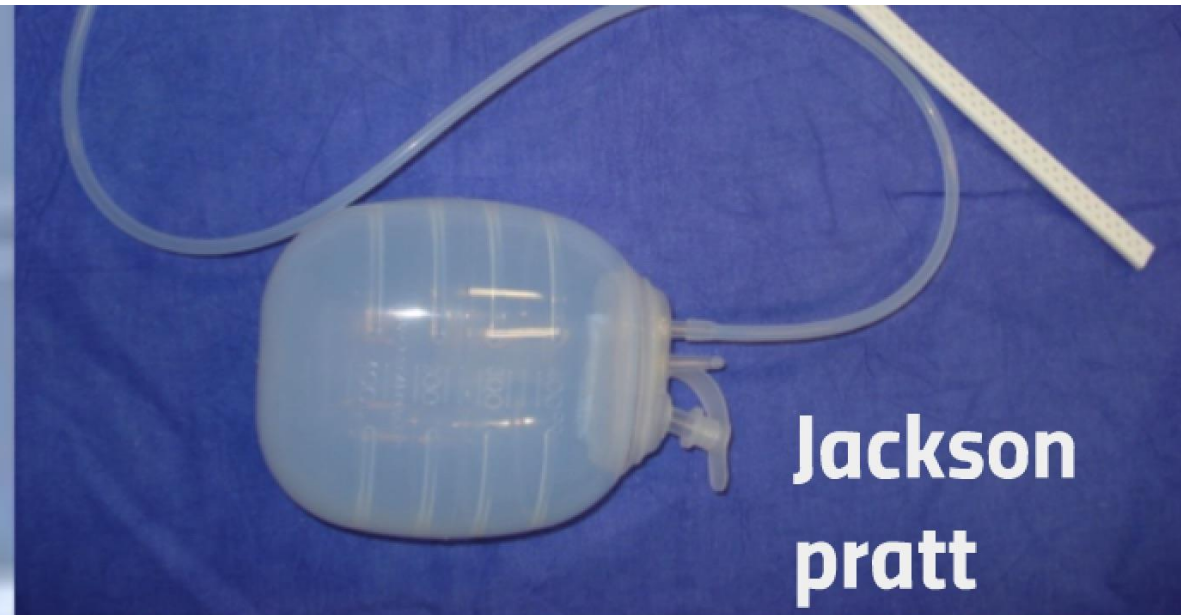



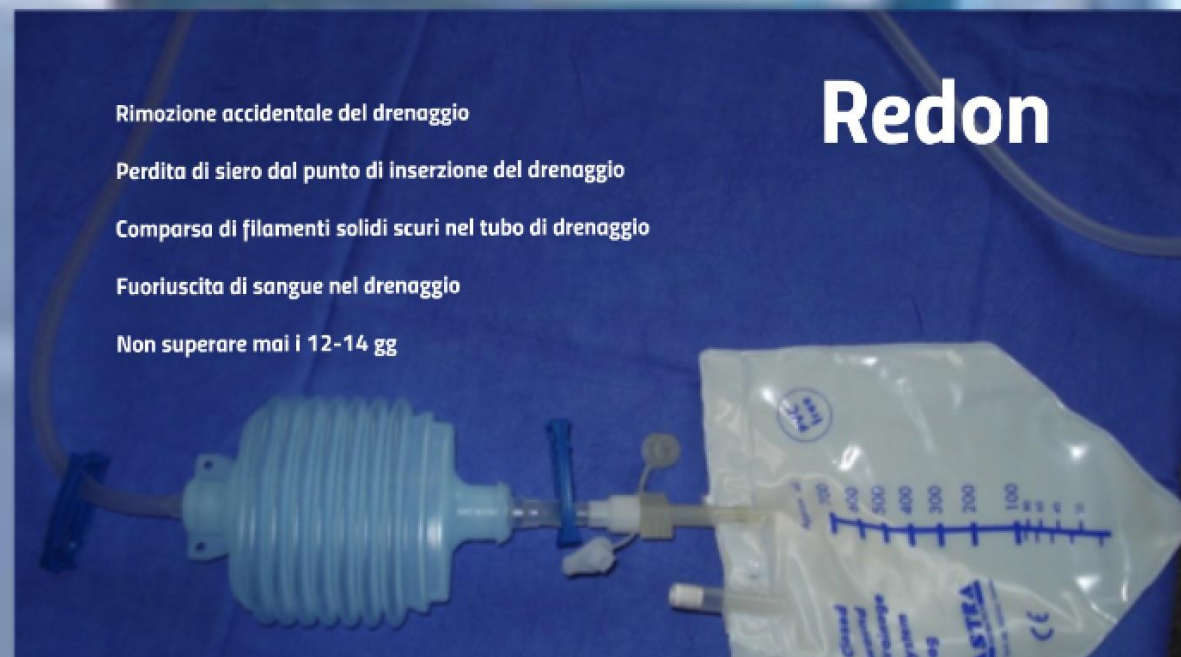


FATIGUE



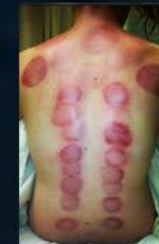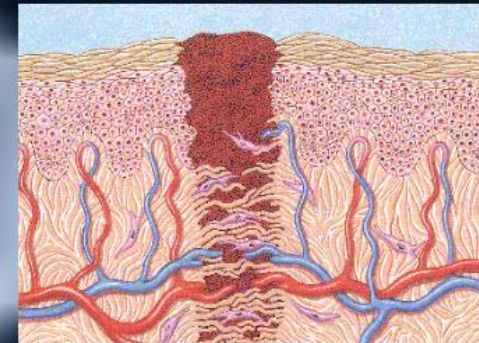
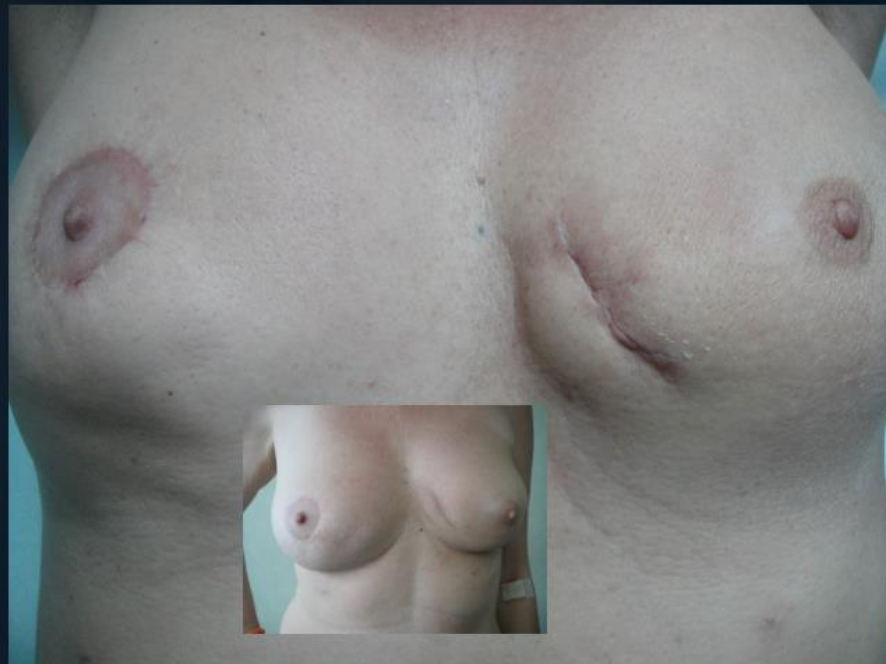

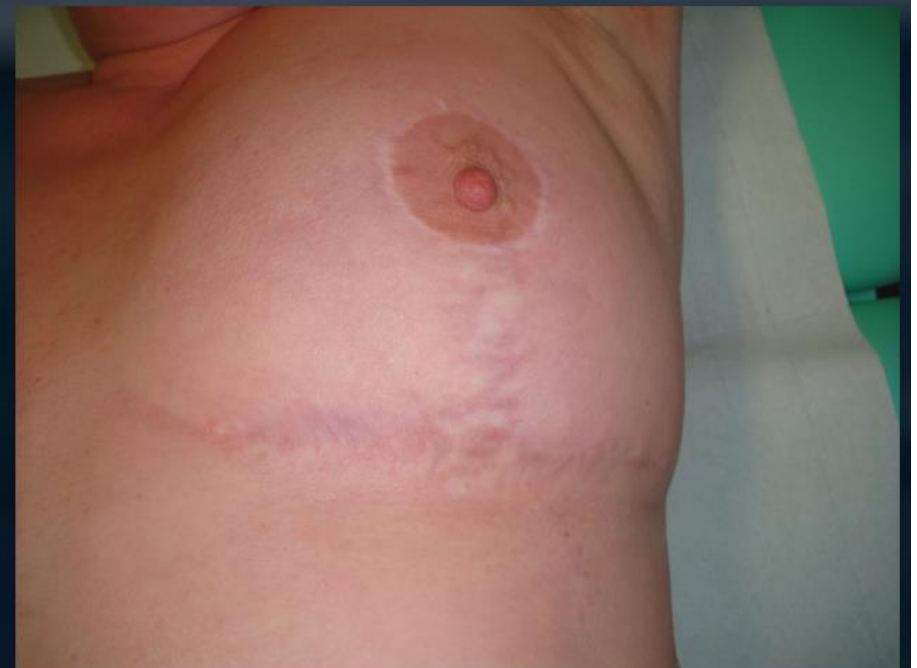
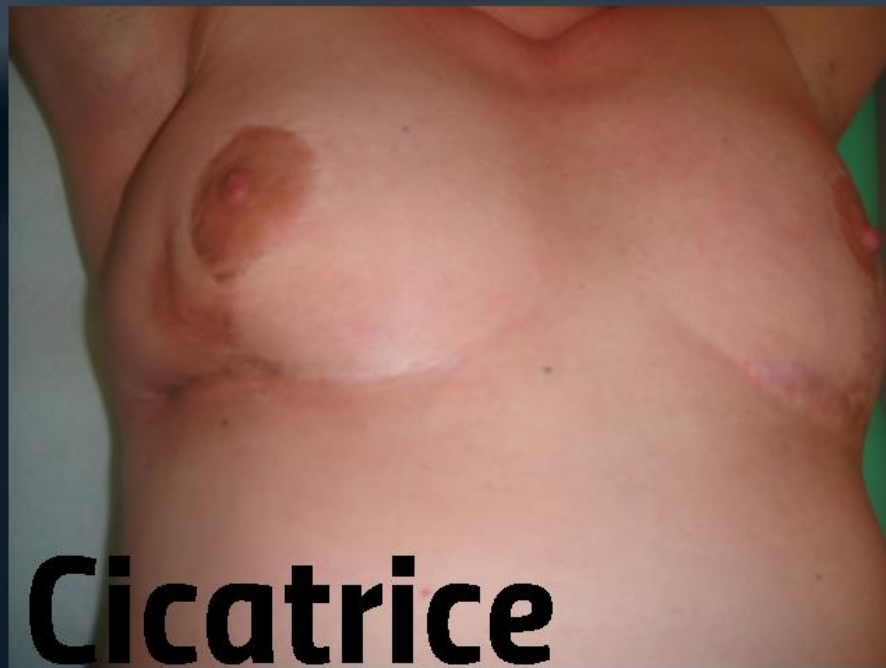**Jackson
pratt**



Redon

- Rimozione accidentale del drenaggio
- Perdita di siero dal punto di inserzione del drenaggio
- Comparsa di filamenti solidi scuri nel tubo di drenaggio
- Fuoriuscita di sangue nel drenaggio
- Non superare mai i 12-14 gg





fabio.sandrin@ieo.it

luizfelipe.nevolateixeira@ieo.it